



Pelvic Lymphocele Enlargement after Manual Lymph Drainage: Case Report and Literature Review

Jaqueline Munaretto Timm Baiocchi^{1*}; Larissa L Campanholi²; Glauco Baiocchi³

¹Department of Physical Therapy, Instituto Oncofisio, São Paulo, Brazil.

²Department of Physical Therapy, Instituto Sul Paranaense de Oncologia, Ponta Grossa, Brazil.

³Department of Gynecologic Oncology, AC Camargo Cancer Center, Sao Paulo, Brazil.

***Corresponding Author(s): Jaqueline Munaretto**

Timm Baiocchi

Department of Physical Therapy, Oncofisio - Rua Joaquim Távora, 04015-000, São Paulo, Brazil.

Tel: +55-11-3255-4727;

Email: jaqueline@oncofisio.com.br

Received: Oct 30, 2020

Accepted: Jan 21, 2021

Published Online: Jan 26, 2021

Journal: Annals of Gynecologic Cancer

Publisher: MedDocs Publishers LLC

Online edition: <http://meddocsonline.org/>

Copyright: © Timm Baiocchi JM (2021). *This Article is distributed under the terms of Creative Commons Attribution 4.0 International License*

Keywords: lymphedema; lymphocele; lymph drainage.

Abstract

Purpose: Lymphocele is a cystic cavity with a fibrous capsule that contains lymphatic fluid. Our objective is to describe physical therapy approach for leg lymphedema after endometrial cancer treatment that resulted in an increase of a pelvic lymphocele.

Client description: A 59-year-old woman with endometrial high-grade adenocarcinoma was referred to our center with a history of pelvic and leg lymphedema followed by a pelvic lump, subsequently diagnosed as pelvic lymphocele.

Intervention: She undertook a physiotherapist-guided complex decongestive therapy program, with manual lymph drainage interventions including intermittent pressure compression and use of compression stockings. Limb and pelvic volumes were measured over a 6-month period.

Measures and outcome: Within the first month, the patient's excess lower limb volume reduced, and lymphocele volume was 300 ml. At 4 months, her lymphocele volume increased to 500ml and at 6-month evaluation the lymphocele decreased to 17 ml, suggesting spontaneous drainage to the abdominal cavity.

Implications: A woman with pelvic and lower leg lymphedema caused by endometrial cancer treatment benefited from reduced swelling despite the lymphocele enlargement. This case provides knowledge about lymphocele behavior after complex decongestive physiotherapy for pelvic and lower leg lymphedema.



Introduction

A lymphocele is a cystic mass that can form in the pelvic retroperitoneum or in the paraaortic region after pelvic or pelvic and paraaortic lymphadenectomy. A lymphocele is a collection of lymph bordered by a thick fibrous wall without vascular supply and epithelial lining, expanding from the retroperitoneum into the pelvis or the abdominal cavity [1].

The pathophysiological basis for lymphocele development is an incomplete lymph stasis with post-operative lymph leakage in an amount exceeding the capacity for spontaneous peritoneal reabsorption and the accumulation of lymph in spaces that have formed as a result of lymphatic tissue removal [2].

Pelvic lymphocele prevalence varies from 0% to 58, 5%. This variation is due to underdiagnosis because the majority is asymptomatic and are often an incidental finding during postoperative or routine follow up [3]. Moreover, large lymphoceles may cause symptoms related to compression of adjacent structures such as lower abdominal pain, abdominal fullness, constipation, increase of urinary frequency, and edema of the genitals and/or legs [4].

The symptomatic lymphoceles rates are reported from 5% to 6% of the cases and its treatment consists of drainage, surgical resection, biological glues or alcoholization [5, 6]. Moreover, significant sequelae could develop and include infection of the lymphocele, obstruction and infection of the urinary tract, intestinal obstruction, venous thrombosis, pulmonary embolism, chylous ascites and lymphatic fistula formation [7].

On clinical examination, a large lymphocele may present as a palpable pelvic mass and the skin may be reddened and swollen. Common signs of all lymphoceles are following: A cyst with thick wall with no vascularization, no intraluminal calcifications and no signs of solid components. The asymptomatic lymphocele is usually a round, unilocular cyst with ground-glass contents and differ from symptomatic which is usually an oval, or ovoid, unilocular cyst with low-level or anechoic content and presence of debris and septations [1].

Imaging such as ultrasound or computed tomography establishes the diagnosis. Other fluid collections to be considered in the differential diagnosis are urinoma, seroma and hematoma. Yet, when lower limb edema is present, venous thrombosis should be considered [7].

The lymphocele development can be related to the tumor aggressiveness, metastatic nodes or by the treatment like number of lymph nodes harvested and use of radiation [5,6]. In addition, sentinel lymph node mapping decreases the risk of lymphocele formation compared to full lymphadenectomy [8].

Lymphedema is characterized by the accumulation of protein rich fluid in the interstitial space because of the lymphatic damage induced by the inguinal, pelvic or paraaortic lymphadenectomy [9]. Lymphedema treatment is made by the Complex Decongestive Therapy (CDT) which consists of manual lymph drainage, intermittent pressure compression, skin care, exercises and use of bandaging or compression garments.

Case report

A 59 years old woman, diagnosed with endometrial high-grade adenocarcinoma (Stage IIIA – FIGO) was submitted to

complete surgical staging on December 19th, 2015, which included resection of 64 pelvic and retroperitoneal lymph nodes, followed by adjuvant chemotherapy. The patient did not receive adjuvant radiotherapy. Previously she already has undergone a melanoma resection at her left thigh with inguinal lymphadenectomy.

She was referred to our center after development of lower limb lymphedema. During physical exam, observed a stage II lymphedema at the left lower limb, supra pubic and pelvic edema. The complementary exams showed no deep vein thrombosis, left and right saphenous vein insufficiency, and collateral and perforating vein with reflux to the popliteal vein. The lymphoscintigraphy reported a dermic reflux at her left foot and preserved lymph drainage at right lower limb. For the lymphedema treatment it was performed CDT with manual lymph drainage, intermittent pressure compression twice a week and the use of 20/30 mmHg compression stocking. The program was delivered under the guidance of a physiotherapist certified in lymphedema therapy.

On January 22th, 2016 she did a computed tomography that revealed the existence of a lymphocele with 300 milliliters, asymptomatic. The patient kept her lymphedema treatment, twice a week, and started Pilates exercises. In April 2016 she had a new tomography that evidenced the growth of the lymphocele into 500 milliliters, evidenced by a symptomatic lower belly lump. After that the patient developed stage I lymphedema at the right lower limb. In her last tomography, on June 22th, 2016, it was noted a sudden decrease, without clinical intervention, of the lymphocele to 17 milliliters, suggesting spontaneous drainage to the abdominal cavity.

In this article, we present a unique case report of a patient that had a benefit from CDT, improving the limb and pelvic volume despite having an enlargement of a pelvic lymphocele. As far as we know, any study have addressed the prevalence of lymphocele in the population with lymphedema, particularly the relation between lymph drainage and lymphocele enlargement.

Considering the pathophysiology of lymphocele, it can be argued that CDT, especially MLD may have contributed to the lymphocele enlargement after improvement of the lymph flow. It is important that oncology health professionals, lymphedema-trained clinicians and patients be informed about the side effects of the lymphedema treatment and be aware of this complications.

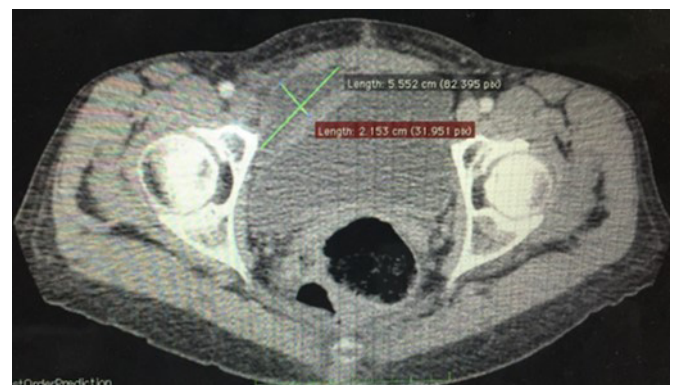

Figure 1: CT aspect of pelvic lymphocele.

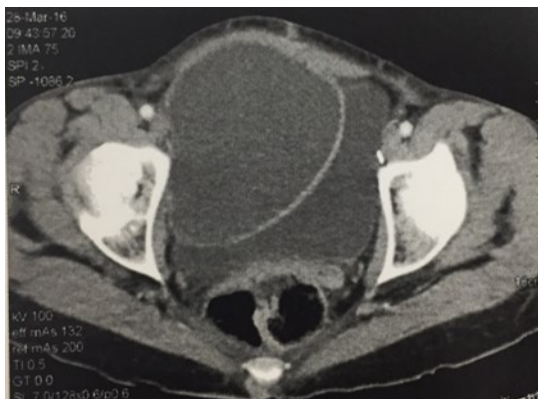


Figure 2: Lymphocele increase after lymph drainage.

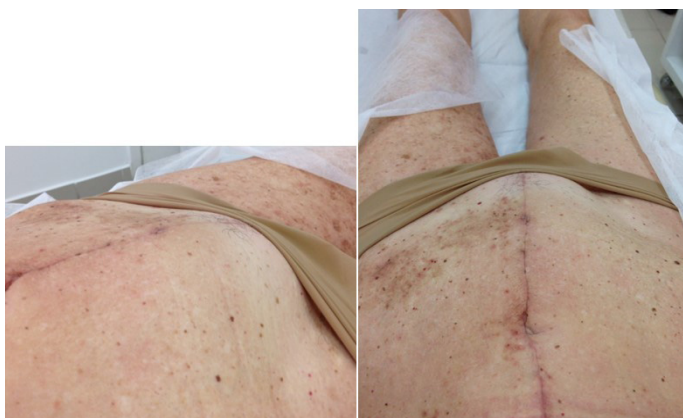

Figure 3: Pelvic aspect of the lymphocele.

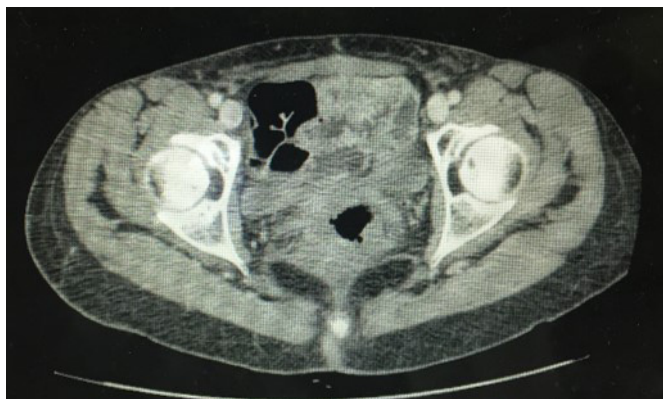

Figure 4: CT aspect after the lymphocele's regression.

Conclusion

In this present case, CDP for the lymphedema treatment contributed to the enlargement of a pelvic lymphocele.

References

1. Weinberger V, Fischerova D, Semeradova I, Slama J, Cibula D, et al. Ultrasound characteristics of a symptomatic and asymptomatic lymphocele after pelvic and/or paraaortic lymphadenectomy. *Taiwan J Obstet Gynecol.* 2019; 58: 266-272.
2. Weinberger V, Cibula D, Zikan M. Lymphocele: Prevalence and management in gynecological malignancies. *Expert Rev Anticancer Ther.* 2014; 14: 307-317.
3. Achouri A, Huchon C, Bats AS, Bensaïd C, Nos C, et al. Postoperative lymphocysts after lymphadenectomy for gynaecological malignancies: Preventive techniques and prospects. *Eur J Obstet Gynecol Reprod Biol.* 2012; 161: 125-129.
4. Metcalf KS, Peel KR. Lymphocele. *Ann R Coll Surg Engl.* 1993; 75: 387-392.
5. Achouri A, Huchon C, Bats AS, Bensaïd C, Nos C, et al. Complications of lymphadenectomy for gynecologic cancer. *Eur J Surg Oncol.* 2013; 39: 81-86.
6. Zikan M, Fischerova D, Pinkavova I, Slama J, Weinberger V, et al. A prospective study examining the incidence of asymptomatic and symptomatic lymphoceles following lymphadenectomy in patients with gynecological cancer. *Gynecol Oncol.* 2015; 137: 291-298.
7. McCullough CS, Soper NJ, Clayman RV, So SS, Jendrisak MD, et al. Laparoscopic drainage of a posttransplant lymphocele. *Transplantation.* 1991; 51: 725-727.
8. Diniz TP, Drizlionoks E, Faloppa CC, Menezes JN, Mantoan H, et al. Impact of Sentinel Node Mapping in Decreasing the Risk of Lymphocele in Endometrial Cancer. *Annals of Surgical Oncology.* 2020.
9. Hareyama H, Hada K, Goto K, Watanabe S, Hakoyama M, et al. Prevalence, classification, and risk factors for postoperative lower extremity lymphedema in women with gynecologic malignancies: A retrospective study. *Int J Gynecol Cancer.* 2015; 25: 751-757.